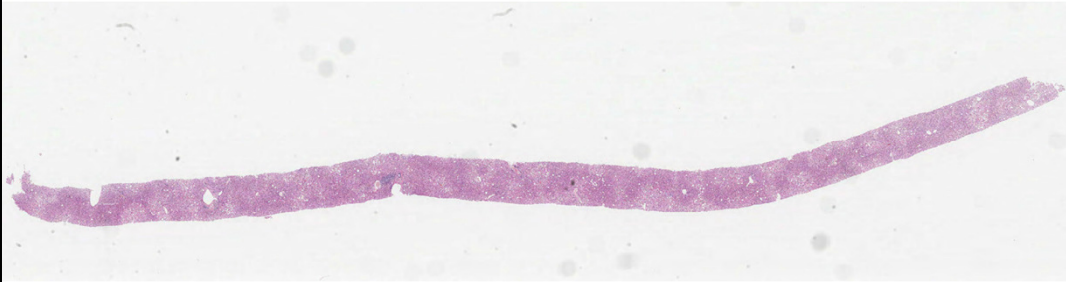


Case LS4 67M

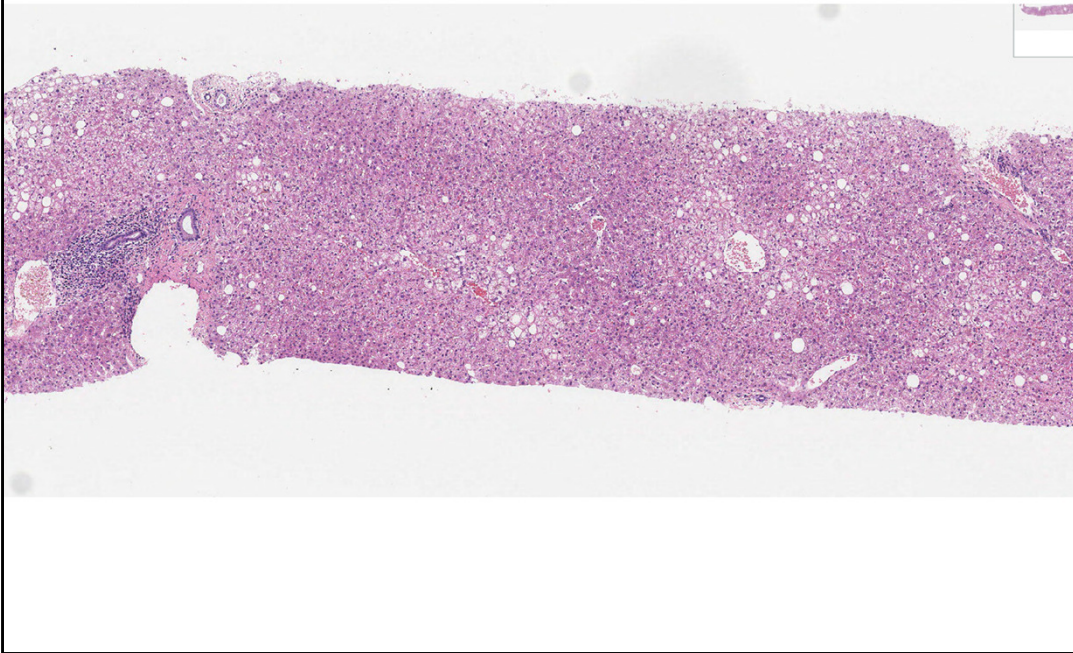
methotrexate for psoriasis, fatty liver on US, elevated P3NP, fibroscan 6kPa.
Risk factors for metabolic liver disease (BMI 32). ? methotrexate liver injury, ?
hepatic fibrosis.

Also van Gieson, retic, Cam 5.2



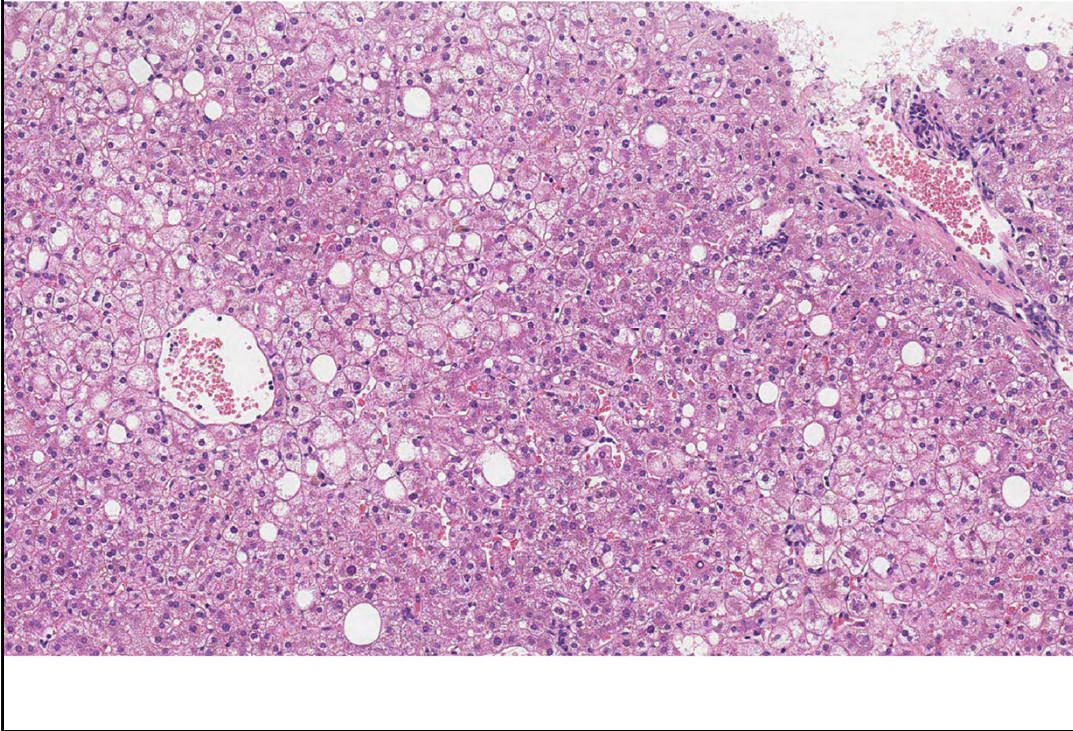
A good core of liver, plenty of portal areas, steatosis visible at low magnification.

LS4



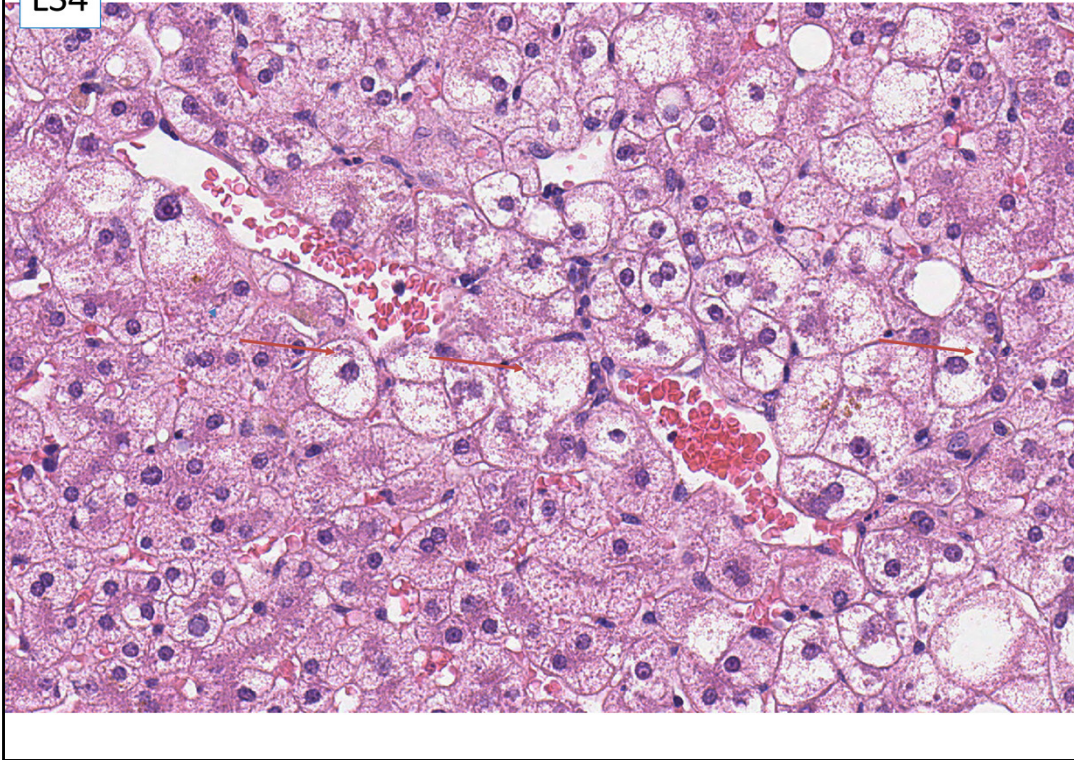
Low magnification – steatosis, chronic inflammatory infiltrate in some of the portal tracts.

LS4



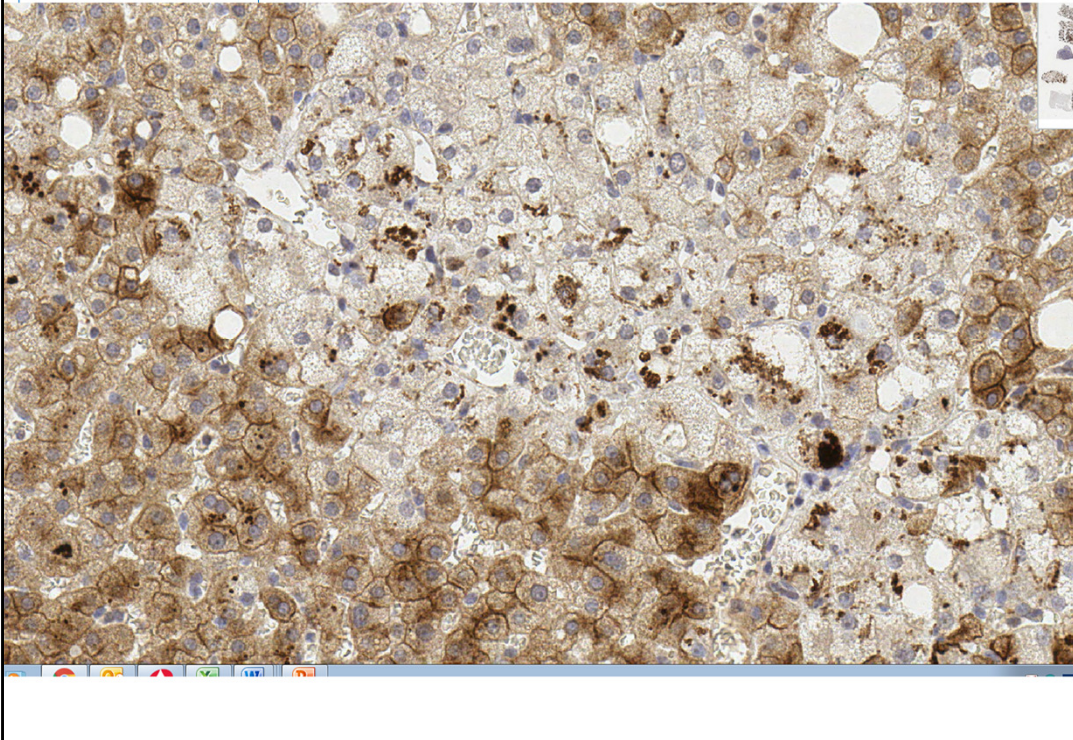
At medium magnification – macrovesicular steatosis, with fat droplets of various size, in a proportion of the hepatocytes.

LS4




High power view of ballooned hepatocytes, some with Mallory Denk bodies (arrow). Ballooned hepatocytes are larger than their neighbours, with rounded outlines, and a fine web of reticular cytoplasmic staining throughout. The Mallory Denk body represents the collapsed condensed bundle of intermediate filaments of the cytoskeleton, which can no longer maintain the normal rectangular shape of the hepatocyte. This results in the ballooned shape of the cell. The oxidative stress results in free radicals which damage the cytoskeleton – this is why ballooned hepatocytes are a direct manifestation of, and diagnostic criterion for, cell injury in steatohepatitis. Steatosis is usually present in other hepatocytes, and sometimes in the ballooned hepatocytes.

LS4 Cam 5.2




If uncertain about Mallory Denk bodies on H&E they can be confirmed by immunohistochemistry – using Cam 5.2, CK8/18, ubiquitin, or p62. This can be useful if the decision between steatosis and steatohepatitis is difficult to make on the H&E stain. However, it is now recognised that the prognosis / risk of progression of steatohepatitis is related to the fibrosis in the biopsy, rather than to the specific characteristics and severity of the steatohepatitis (steatosis, ballooning or Mallory Denk bodies).

LS4 reticulin



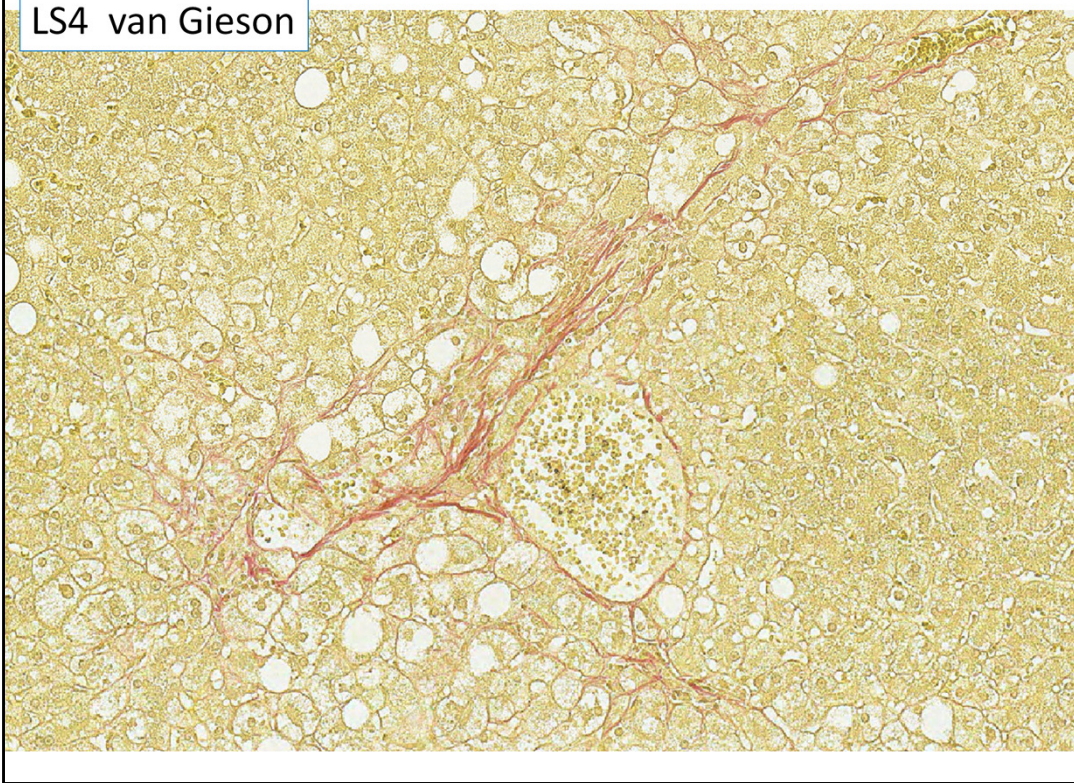
Reticulin stain – there is not bridging fibrosis, and overall vascular architecture (arrangement of portal and venular areas) appears to be preserved.

LS4 van Gieson



Low magnification – early stage fibrosis

LS4 van Gieson



High magnification – early pericellular fibrosis is best seen on the van Gieson or other stain for type 1 collagen – which is normally only present in the portal tracts and hepatic vein walls.

Case LS4 67M

methotrexate for psoriasis, fatty liver on US, elevated P3NP, fibroscan 6kPa.
Risk factors for metabolic liver disease (BMI 32). ? methotrexate liver injury, ?
hepatic fibrosis.

Also van Gieson, retic, Cam 5.2

A	Steatosis. Comment on fibrosis. Alcohol or non alcohol related +/- drug injury
B	Steatohepatitis. Severe fibrosis. Alcohol or non alcohol related +/- drug injury
C	Glycogenic hepatopathy. Comment on fibrosis.
D	Methotrexate related fibrosis.
E	Steatohepatitis. Mild fibrosis. Alcohol or non alcohol related +/- drug injury

Case LS4 67M

methotrexate for psoriasis, fatty liver on US, elevated P3NP, fibroscan 6kPa.
Risk factors for metabolic liver disease (BMI 32). ? methotrexate liver injury, ?
hepatic fibrosis.

Also van Gieson, retic, Cam 5.2

A	Steatosis. Comment on fibrosis. Alcohol or non alcohol related +/- drug injury
B	Steatohepatitis. Severe fibrosis. Alcohol or non alcohol related +/- drug injury
C	Glycogenic hepatopathy. Comment on fibrosis.
D	Methotrexate related fibrosis.
E	Steatohepatitis. Mild fibrosis. Alcohol or non alcohol related +/- drug injury

Correct answer: E.

The response includes three required components. These are: the morphological pattern – steatohepatitis; the stage – mild fibrosis, and the aetiology – alcohol or non-alcohol related +/- drug related.

Steatohepatitis – necessary features are steatosis, ballooning and inflammation.

Mallory Denk bodies are more objective, while ballooning is less reproducible. There is very mild fibrosis, which is in keeping with the low fibroscan result. With BMI of 32, this is consistent with non-alcoholic steatohepatitis. Methotrexate is synergistic with other causes of fatty liver disease, so is contraindicated in patients who already have fatty liver disease with fibrosis. The answer would be better by naming Methotrexate, rather than non-specific 'drug injury'. Alcohol could result in the same appearances, so needs to be excluded clinically.

Comments on other options:

A. Steatosis – there is clearly hepatocyte ballooning, inflammation can be very mild in steatohepatitis. The presence of characteristic periellular fibrosis shows that there is liver scarring from the steatohepatitis.

B, The fibrosis is very mild/early, not severe.

C. Glycogenic hepatopathy is a pattern of liver injury seen in poorly controlled type 1 diabetes. The hepatocytes are all large and pale, plant-like, with the same appearances as in glycogen storage disease, without an inflammatory component.

D. The early fibrosis may be methotrexate related, but the additional features of steatohepatitis are important in explaining this.